

**PATIENT**

Osito Dunn

**SPECIES**

Canine

**BREED**

Bichon Poodle Mix

**SEX**

Male neutered

**AGE**

14 years

**WEIGHT**

14.7lbs

**INTERPRETED BY**

Maggie Machen Lamy,  
DVM, DACVIM  
(Cardiology)

**IMAGING PERFORMED BY**

Loetitia Saint-Jacques,  
LVT

**HOSPITAL NAME**

Roundhill AH

**REFERRING VET**

Dr. Kelly

**INVOICE**

47699

**DATE**

4/27/26

**PRESENTING CLINICAL SIGNS**

History: Recheck echo. Grade 5/6 heart murmur; loudest over left side. BP: 170/120 (Pimobendan was not given as scheduled on the day the blood pressure was taken). CXR on 4/22 revealed radio-dense circumscribed area central caudal-dorsal lung fields superimposed over vena cava/caudal esophagus area on both lateral views. Review of radiographs from past years shows a smaller lesion in the same location. Current medications: 1.875 Pimobendan BID, Thyroxine 0.1mg BID and Vetsulin u-4- insulin, 3 units in A.M. and 2 in P.M. with food.

-Pertinent previous echo findings (10/2025 Cardiac Vet): CVD B1. Normal LV, mild LAE, mild to moderate MR. Improved from previous; continue Pimobendan.

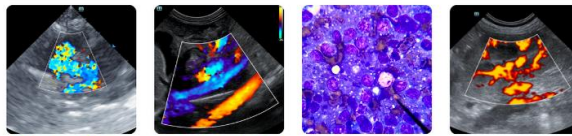
**ECHOCARDIOGRAM FINDINGS**

2D, m-mode, color flow and doppler imaging is available. Diffuse thickening of mitral valve leaflets (anterior>posterior) with mild prolapse into the left atrial lumen. Moderate eccentric mitral regurgitation with mild left atrial dilation. Normal MR velocity. Normal LV diameter with hyperdynamic myocardial function. The tricuspid valve appears subjectively normal, with trace tricuspid regurgitation. Normal velocity. Normal right atrial and ventricular diameter. The pulmonic and aortic valves are normal in morphology and mobility. Normal pulmonic and aortic outflow velocities. No aortic or pulmonic insufficiency. No pericardial or pleural effusion noted. No cardiac tumors observed.

**CARDIAC CHART**

CANINE CARDIAC PARAMETERS	MR VMAX (m/s)	TR VMAX (m/s)	LA/AO (Boon method)	LA/AO (Heart Base; Swe)	FS (%)	EF (%)	EPSS (cm)
<b>NORMAL PARAMETER</b>	4.5-5.5	<2.7	1.3	<1.6	28-40	40-100	<0.6
<b>PATIENT</b>	5.2	2.2	NM	1.5	48	81	0.2
CANINE CARDIAC PARAMETERS	HR (BPM)	AV VMAX (m/s)	PV MAX (m/s)	BODY WEIGHT (kg)	LA 2D short axis Base view (cm)	LVIDd Avg; 2D and m-mode short axis (cm)	LVIDs Avg; 2D and m-mode short axis (cm)
<b>NORMAL PARAMETER</b>	50-100	0.7-1.7	0.7-1.6	BELOW	BELOW	BELOW	BELOW
<b>PATIENT</b>	NM	1.2	1.2	6.7	2.2	2.6	1.4
<b>*Normal chamber parameters expressed as a mean value (SD)</b>				3	1.27 (5.3)	2.46 (2.46)	1.36 (5.5)
<b>BODY WEIGHT DEPENDENT PARAMETERS</b>				5	1.40 (4.5)	2.74 (5.2)	1.60 (4.7)
<i>*Note: All measurements based upon multi-modal images and methods. An average value is reported.</i>				10	1.50 (3.8)	3.27 (3.5)	2.06 (3.1)
				15	1.83 (2.0)	3.71 (2.4)	2.43 (2.1)
				20	2.02 (1.9)	4.14 (2.2)	2.80 (2.0)
				25	2.18 (2.4)	4.48 (2.9)	3.10 (2.5)
				30	2.33 (3.3)	4.83 (3.9)	3.39 (3.4)
				35	2.48 (4.3)	5.17 (5.0)	3.69 (4.5)
				40	2.62 (5.2)	5.48 (6.1)	3.96 (5.4)
				50	2.88 (7.1)	6.07 (8.3)	4.46 (7.4)

Adapted from June Boon, Veterinary Echocardiography, 1998  
Rishniw M and Hollis NE, J Vet Intern Med 2000; 14:429-435  
Hansson et al, Vet Rad and Ultrasound 2002  
Bonagura et al. Echocardiography: principles of interpretation, Vet Clin North Am 15:1177, 1995



**PATIENT**

Osito Dunn

**SPECIES**

Canine

**BREED**

Bichon Poodle Mix

**SEX**

Male neutered

**AGE**

14 years

**WEIGHT**

14.7lbs

**INTERPRETED BY**

Maggie Machen Lamy,  
DVM, DACVIM  
(Cardiology)

**IMAGING  
PERFORMED BY**

Loetitia Saint-Jacques,  
LVT

**HOSPITAL NAME**

Roundhill AH

**REFERRING VET**

Dr. Kelly

**INVOICE**

47699

**DATE**

4/27/26

**INTERPRETATION OF THE FINDINGS & FURTHER RECOMMENDATIONS**

Compared to serial evaluations, the findings remain similar, which is good news given the time frame. Moderate MR and trace TR are unchanged with only mild left atrial enlargement. No additional issues are seen.

Given these findings, reasonable to continue Pimobendan lifelong as prescribed with no obvious indication for additional medications. Continued assessment of progression is recommended, with a guarded prognosis (stage B2). Patient may be at risk for development of CHF, arrhythmias, and/or sudden death going forward.

Omega fatty acid supplementation and mild salt restriction may also be of some long-term benefit. Monitor for development of a progressive cough, labored breathing, exercise intolerance or collapse episodes.

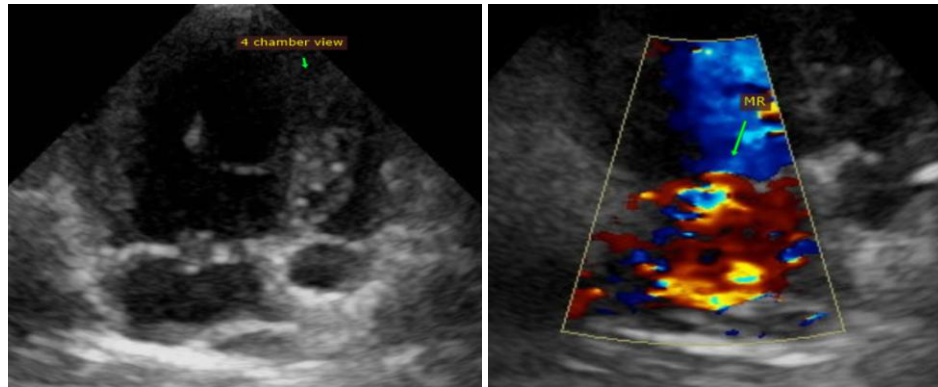
Anesthetic risk remains mildly elevated. Cardiac protective drug choices (opioid/benzodiazepine premedication, Propofol or alfaxalone induction, iso or sevo gas) are recommended. Monitor for arrhythmias, hypotension, and hypoxia both intra and post-operatively and intervene as necessary. Judicious IV fluid rates are recommended to avoid fluid overload. Avoid heart rate stimulating drugs such as atropine unless clinically indicated.

**PLAN**

Baseline BP recommended every 6 months. Continue Pimobendan 0.25-0.3mg/kg PO q12h.

Recommend monitor for progression with a recheck echocardiogram in 6-9 months, sooner if any development of clinical signs.

**IMAGES**



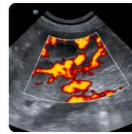
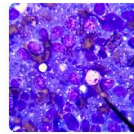
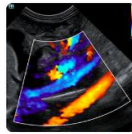
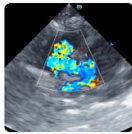
**The information and recommendations provided are based on the images presented by the referring veterinarian. No evaluation can be communicated regarding pathology that was not visible in the image/video clips provided.**

Thank you for this referral. This report was generated using transcription software, and minor dictation errors may be present. If the clinical or image interpretation does not parallel your findings

Imaging  
performed by



Paw Print Veterinary Services, Inc.  
pawsonography@gmail.com  
530-786-8340



**Clinical Sonography & Telectology**  
Educational Teleconsultation Services™

**SonoPath**

FOSTERING THE ART OF VETERINARY MEDICINE™

SonoPath.com info@sonopath.com 1.800.838.4268

**PATIENT**

or if I can be of any further assistance, please contact me.

Osito Dunn

**Maggie Machen Lamy, DVM**

**SPECIES**

**Diplomate of the American College of Veterinary Internal Medicine (Cardiology)**

Canine

info@sonopath.com

**BREED**

Bichon Poodle Mix

**SEX**

Male neutered

**AGE**

14 years

**WEIGHT**

14.7lbs

**INTERPRETED BY**

Maggie Machen Lamy,  
DVM, DACVIM  
(Cardiology)

**IMAGING  
PERFORMED BY**

Loetitia Saint-Jacques,  
LVT

**HOSPITAL NAME**

Roundhill AH

**REFERRING VET**

Dr. Kelly

**INVOICE**

47699

**DATE**

4/27/26